

GLAUCOMA

THE EYE NEWSLETTER • VOLUME XVIII • FALL, 1996
ROBERT M. SCHARF, M.D. • 596-3328

What Is Glaucoma?

Did you know that glaucoma is a leading cause of blindness in people over 40 — and were you aware that almost all blindness due to glaucoma can be prevented?

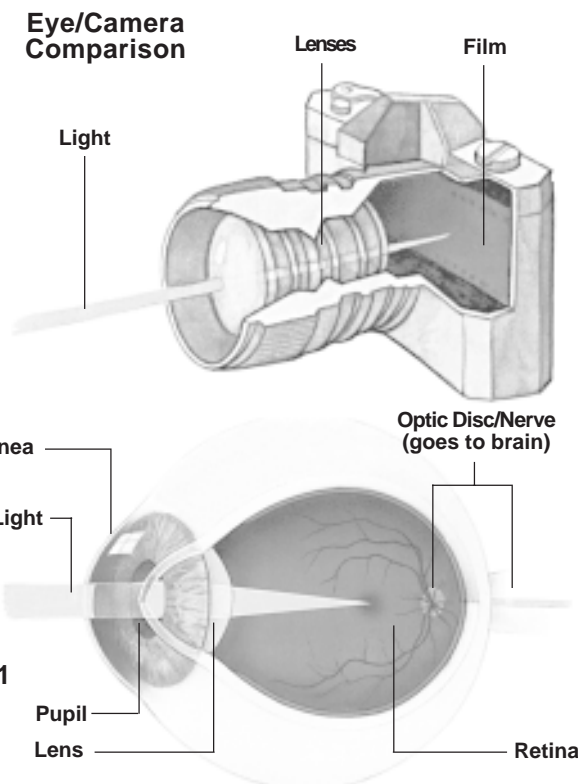
Glaucoma is a condition in which the pressure created by the fluid (aqueous) in the eye is relatively too high. With the elevated eye pressure, blood is less able to enter the back of the eye to keep the optic nerve healthy. A normal intraocular pressure is usually in the 10 to 20 mm Hg range, although normal can be from 7 mm Hg to 27 mm Hg. When this pressure (called intraocular pressure) remains abnormal over a period of time, damage occurs to the delicate structures of the optic nerve and retina. If this abnormal pressure is left untreated, damage is progressive and blindness often is the result. Glaucoma usually affects both eyes, but it can involve only one eye.

In order to understand how the abnormal pressure can damage your eye, we will take a look at how the eye works.

A Look Inside the Eye. The eye functions like a highly sophisticated camera. The front of the eye is covered by a transparent membrane called the cornea. The iris opens and closes, like the diaphragm of a camera, to control the amount of light that enters through the pupil. The lens focuses the light onto the retina which, like the film in a camera, records light images. The retina sends the visual messages to the optic disc. These messages are then transmitted to the brain by way of the optic nerve.

The front part of the eye (Fig. 2A and B), the anterior and posterior chambers, is filled with a fluid called aqueous. Aqueous helps to maintain normal pressure inside the eye, which prevents the eyeball from collapsing like a grape. Aqueous is constantly being produced by the ciliary body and drains through the trabecular meshwork (Fig. 2A and B) where it returns to the bloodstream.

Why Does Glaucoma Occur? The most common reason why glaucoma occurs is that the aqueous does not drain through the trabecular meshwork adequately and, as a result, the pressure slowly rises in the eye. In less common cases, the pressure in the eye can be normal, but the blood supply to the back of the eye is impaired. In either instance, the blood supply to the retina and the optic disc is reduced and irreversible damage can occur. When this happens, the transmission of visual messages to the brain is interrupted. The result is impaired vision and, ultimately, blindness.



Open Angle Glaucoma

What Can You Do? One out of every 50 persons over the age of 40 has glaucoma. Your best defense is to have regular eye examinations. It is recommended that everyone over the age of forty have a regular eye examination every two to three years. Every three to five years between examinations is sufficient for those under the age of 40. Even when glaucoma is diagnosed, it cannot be cured without surgery; but in 95% of cases, it can be controlled and damage progression can be stopped with medication. Early detection and treatment are the only ways to prevent permanent loss of vision.

Types of Glaucoma. There are numerous types of glaucoma, all of which are caused by an abnormal intraocular pressure. Glaucoma can result from various diseases, inflammatory conditions, injury, and vascular abnormalities. Congenital glaucoma that affects newborns can also occur. The most common (95%) type of glaucoma is chronic open angle.

Chronic Open Angle Glaucoma (Fig. 2A). There are absolutely no symptoms or warnings that damage is occurring. The pressure rise is so slow that pain never occurs and damage can develop so gradually that the patient may have a severe visual loss before he is aware anything is wrong. You can actually maintain 20/20 central vision even if 90% of your peripheral vision has been lost.

Acute Angle Closure Glaucoma (Fig 2B). This is a more rare form of glaucoma in which the rise of pressure is so rapid (because the iris closes over the trabecular meshwork) that the involved eye becomes suddenly red, extremely painful, and is accompanied by nausea and vomiting. The treatment is emergency surgery by making a hole in the iris (iridectomy) for the aqueous to access the trabecular meshwork directly.

Ocular Hypertension. Ocular hypertension is a condition where the eye has an elevated intraocular pressure in the presence of both a normal optic disc and a normal visual field. Usually, we watch this type of patient carefully with regular pressure tests and visual field examinations. Some of these patients change into true glaucoma patients eventually and require treatment. Others never show any ocular damage and treatment is not necessary. We never know which patient will and which patient will not change into the true glaucoma patient.

Low Tension Glaucoma. Glaucoma is not really just elevated intraocular pressure. It is actually the presence of optic disc and visual field damage no matter what the intraocular pressure readings show. That is also why there can be patients that have "low tension glaucoma". In these cases, there is some form of vascular insufficiency to the back portion of the eye. This results in optic nerve and visual field damage from a lack of blood flow even in the presence of normal intraocular pressure readings. These patients still have to be treated to prevent further visual loss by reducing the intraocular pressure.

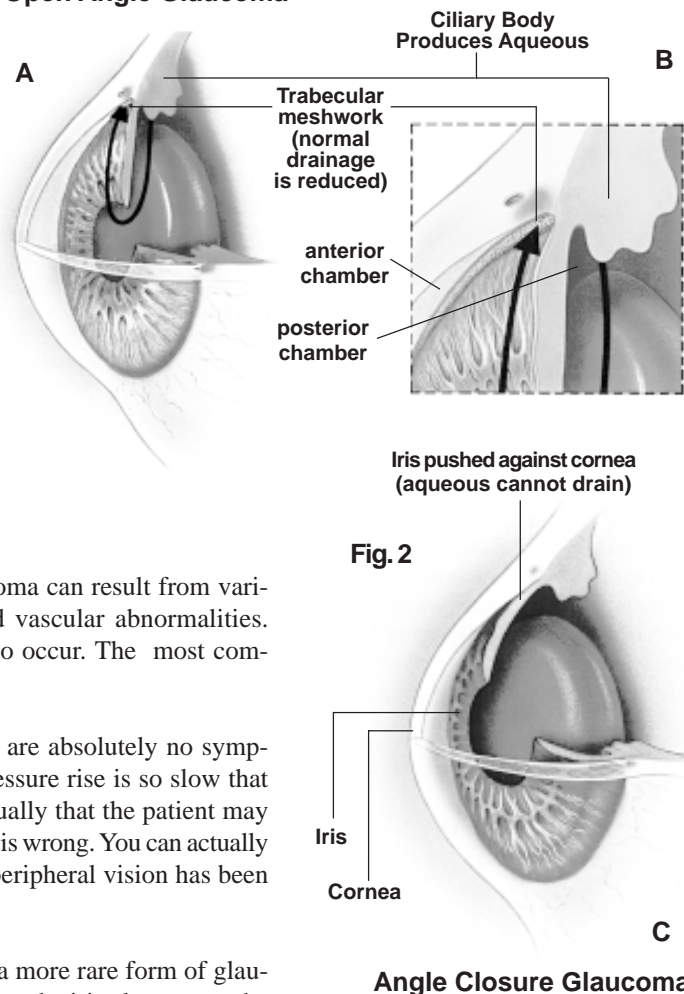
The Eye Examination

Medical History. Your family history with any occurrence of glaucoma and any medications you may take are important basic facts.

Vision Test. Measuring your visual acuity is the initial step in any eye examination.

Slit Lamp Examination. The slit lamp is a type of microscope that allows for a magnified view of the cornea, anterior chamber, trabecular meshwork, lens, and all of the internal parts of the eye.

Ophthalmoscope. The internal parts of the eye behind the iris can be examined with the ophthalmoscope. Evaluating the appearance of the optic disc is the most critical step in assessing the effects of glaucoma on the eye.



Specific Tests for Diagnosing Glaucoma

The diagnosis of glaucoma is confirmed by a series of diagnostic tests that can identify the signs of glaucoma at any stage of development.

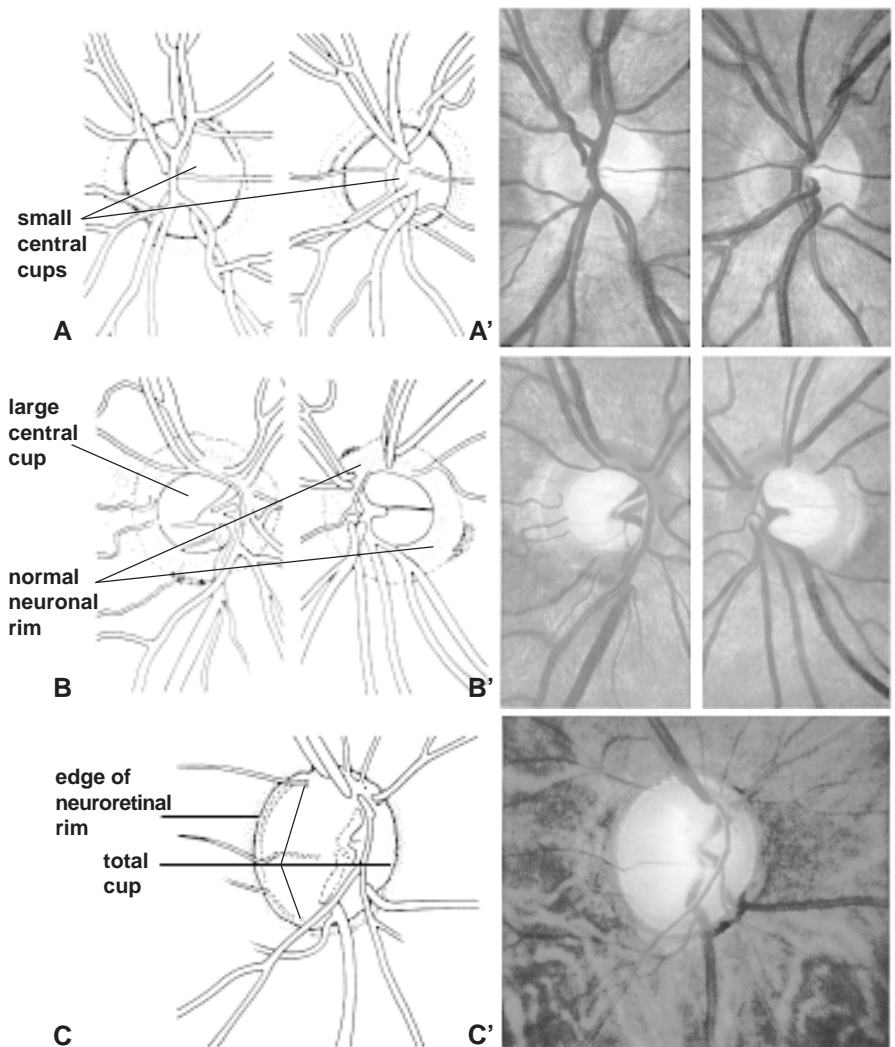
Tonometry. Tonometry is a routine test designed to measure the internal pressure of the eye. It is a screening test just as taking one's blood pressure can determine if the blood pressure is elevated or in the normal range. These tests cannot tell whether or not the eye or heart is healthy. There are several types of tonometers. Depending on the method employed, you may have an anesthetic drop placed in your eye first. One tonometer (Schiotz) has a small weight that rests on the cornea of the eye while you are lying down on your back. Another type (non-contact) sends a puff of air against the cornea to depress it. The most effective test (applanation) lightly pushes a flat plastic tip against the cornea. Of these three tests, only the air puff type can be felt by the patient.

Optic Disc Evaluation. Observation of the optic disc is fundamental to the management of any patient with abnormal intraocular pressure. On examination, it is important to evaluate the size and shape of the disc, the size of the central cup, the color and shape of the neuronal rim of the disc, notching and pallor of the rim, and undermining of the blood vessels. Glaucoma damage is especially suspect when the ratio of the cup surface to the surface area of the entire optic disc is greater than 0.6.

The optic disc in Fig. 3A and A' shows only a minimal and normal optic cup. Fig. 3B and B' show a moderate 0.5 to 0.6 cup that is still normal. Fig. 3C and C' show an end-stage optic disc with essentially no neuronal tissue remaining. The loss of neuronal tissue correlates directly with a loss in the field of vision for that eye. For example, if there is a loss of the inferior neuronal rim (as with a notch), there will be a corresponding loss of a portion of the superior visual field.

Visual Field Examination. This examination is a test of your central and peripheral vision and measures the ability of your eye to respond to different levels of light in the various parts of your retina. Because glaucoma reduces the ability of your eye to respond to light, this test helps determine whether your eye has been damaged by glaucoma. It is similar to performing an electrocardiogram on your heart to determine whether your elevated blood pressure has damaged your heart. In our office, we use the latest computerized type of visual field machine (Perimeter, Fig. 4). Using one eye at a time, you look at the central fixation point of the perimeter, and the automated perimeter will randomly test different parts of your vision. We store the information on a hard drive so that we can electronically compare your fields done at a later date to the earlier fields to see if your fields are staying stable or are developing a progressive loss of vision.

Fig. 3 Optic Disc Cup/Disc Comparison



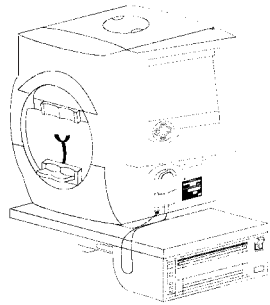
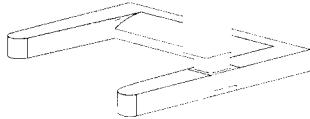


Fig. 4
Perimeter



As can be determined from an evaluation of the optic disc, a normal optic disc has a shallow up to a medium sized surface depression (cup) and, therefore, a full field of vision. Abnormal intraocular pressure causes the optic disc surface nerve fibers to die and wither away creating a larger cup. This may take years to occur and there are no warnings. You can see the effect on the field of vision with the progressive loss of field. As the abnormal pressure continues, the central fibers of the optic disc are further destroyed and the visual field can be reduced to just a small area of light perception vision.

The evaluation of the visual fields starts with Fig. 5A with the normal blind spot as there are no visual cells on the surface of the optic disc. The optic disc is located between ten and twenty degrees nasal (towards the nose) to the center of the retina. The blind spot is seen temporally (towards the side of the face) because the retina takes a picture like a camera: upside down and backwards. When glaucoma damage starts, the

most sensitive areas to damage are in an arc starting from the optic disc and extending both inferiorly and superiorly (Fig. 5B, C, and D) and a nasal step (Fig. 5D). These defects can coalesce and progress to the periphery of the field and eventually cause total blindness (Fig. 5E and 5F).

Treating Glaucoma

Chronic Open Angle Glaucoma. This is the most common type of glaucoma and the most successful treatment for chronic glaucoma is the use of eye drops. There are numerous kinds of drops that may be used only once or twice each day or possibly up to four times each day. Over 95% of chronic glaucoma can be successfully treated with one or more eyedrops and this prevents the loss of vision. Occasionally, pills (a diuretic) have to be added to the routine. A laser procedure (argon laser trabeculoplasty/ALT) or a trap-door surgical trabeculectomy can be performed to create a new drainage site for the aqueous fluid to leave the eye. This is necessary when the patient continues to lose vision even while using a maximum combination of medications. In the last few years, ALT has shown promising benefits and can delay or eliminate the need for an actual surgical procedure such as a trabeculectomy. There is even a trend to use ALT as an alternative to the lifelong use of eye drops.

Acute Angle Closure Glaucoma. The most successful treatment for acute angle closure glaucoma is the use of a laser to cut a small opening in the iris to allow the aqueous fluid to easily pass through from behind the iris into the anterior chamber and then through the trabecular meshwork. This allows the narrow angle (Fig. 2B) to deepen and helps restore a more normal flow of aqueous fluid.

Low Tension Glaucoma. Even though the intraocular pressure may never be higher than 17 mm Hg, low tension glaucoma is treated just as is chronic open angle glaucoma.

Remember: Glaucoma can easily steal your vision without warning. You can protect yourself by just having regular examinations - every two to three years after the age of forty. Glaucoma can be detected early and the early use of medication or surgery can help save your eyesight.

Fig. 5 Progressive Visual Field Damage

